



Piggyback Stacking and Booster Clipping Technique: A Technical Note

Derek O. Pipolo¹, Mickaela Echavarría Demichelis², Cynthia Purves³, Alvaro Campero^{1,4}, Juan F. Villalonga^{1,4}, Sabino Luzzi^{5,6}, Matías Baldoncini^{2,7}

In certain cases, the closing force of a single vascular clip is not sufficient for complete aneurysmal occlusion, and the use of multiple clips, or clip stacking, is required. Many stacking techniques have been described in the literature, such as in tandem stacking and overstacking. However, these may not be feasible during procedures with limited exposure or narrow corridors. Clip reinforcement with a second high-pressure booster clip, also known as the piggyback technique, is an alternative for these cases along with anatomically complex aneurysms or aneurysms demonstrating atypical morphological features. Although this technique has been cited as a potential resource for certain aneurysms, descriptions of its characteristics and advantages are scarce. The purpose of this technical note was to discuss our experience with the piggyback clipping technique and use of a booster clip for a partially embolized and recanalized saccular posterior communicating artery aneurysm in a 50 year-old patient.

INTRODUCTION

The principles of intracranial aneurysm surgery include complete aneurysmal occlusion; preservation of blood flow in the parent and neighboring vessels; and prevention of regrowth, rerupture, or mass effect on adjacent neurovascular structures.^{1,2} All of this can be achieved in most cases by simple surgical clipping, which entails exposure of the aneurysm neck and isolation of the lesion from normal circulation employing a single aneurysm clip.^{1,3,4} However, owing to the anatomical complexity and distinct morphological

features of certain aneurysms (e.g., giant aneurysms, aneurysms containing cholesterol or calcium plaques), the closing force of a single clip is not sufficient for complete occlusion. For these cases, the use of multiple clips, or clip stacking, is required.^{2,4,5}

Many stacking techniques have been described in the literature, with the most common types being in tandem/parallel stacking and overstacking or understacking.⁴ However, these techniques can be counterproductive or are not feasible during procedures with limited exposure or narrow corridors. Reinforcement of the definitive initial clip with a second high-pressure booster clip, also known as the piggyback technique, is an effective alternative. Although this clipping technique has been cited by many authors as a useful resource for complex aneurysms, descriptions of its characteristics and advantages are scarce. The purpose of this technical note was to discuss our experience using the piggyback clipping technique and use of a booster clip for a partially embolized and recanalized saccular posterior communicating artery (PCOM) aneurysm in a 50-year-old patient.

CASE DESCRIPTION

We describe the piggyback clipping technique in an atypical cerebral aneurysm employing a vascular booster clip. The booster clip used for our case was a standard type 7.0-mm curved T2 Sugita clip (Mizuho Medical, Tokyo, Japan) (Figure 1). The clip is composed of a cobalt-chromium-nickel-molybdenum-iron alloy, featuring an integrated coil spring, alligator-type mechanism of closure and a closing force of 2.75 N.

A 50-year-old woman with a past medical history of subarachnoid hemorrhage owing to rupture of a left PCOM aneurysm with subsequent endovascular treatment (embolization) 5 years prior presented with a 15-day history of sudden moderate persistent headache. Cerebral computed tomography angiography

Key words

- Aneurysm clipping
- Booster clip
- Cerebral aneurysm
- Piggyback stacking

Abbreviations and Acronyms

PCOM: Posterior communicating artery

From the ¹LINT, Facultad de Medicina, Universidad Nacional de Tucumán, Tucumán, Argentina; ²Department of Neurological Surgery, Hospital San Fernando, Buenos Aires, Argentina; ³Division of Interventional Neuroradiology Juan A. Fernandez Hospital and Güemes Clinic, Buenos Aires, Argentina; ⁴Department of Neurological Surgery, Hospital Padilla, Tucumán, Argentina; ⁵Neurosurgery Unit, Department of Clinical-Surgical, Diagnostic

and Pediatric Sciences, University of Pavia, Pavia, Italy; ⁶Neurosurgery Unit, Department of Surgical Sciences, Fondazione IRCCS Policlinico San Matteo, Pavia, Italy; and ⁷Laboratory of Microsurgical Neuroanatomy, Second Chair of Gross Anatomy, School of Medicine, University of Buenos Aires, Buenos Aires, Argentina

To whom correspondence should be addressed: Derek O. Pipolo, M.D.
[E-mail: derekipolomd@gmail.com]

Supplementary digital content available online.

Citation: *World Neurosurg.* (2022) 164:306-309.

<https://doi.org/10.1016/j.wneu.2022.05.106>

Journal homepage: www.journals.elsevier.com/world-neurosurgery

Available online: www.sciencedirect.com

1878-8750/\$ - see front matter © 2022 Elsevier Inc. All rights reserved.




Figure 1. (A–F) Piggyback stacking technique using a T2 Sugita standard straight clip with a curved T2 Sugita booster clip. The booster clip is applied over the standard straight clip, supplementing jaw compression

and conveying higher closing force over the aneurysmal neck. (Images used with permission of Mizuho Medical Co., Ltd.)

displayed recanalization of the previously embolized aneurysm along with an undiagnosed ipsilateral anterior choroidal aneurysm (**Figure 2A**). Owing to the patient's symptoms, surgical clipping of both aneurysms was indicated (**Video 1**).

The patient was positioned supine, with the head fixed in a 3-pin headholder and rotated 45° to the contralateral side. A left pterional approach was carried out, and dissection of the sylvian fissure was performed with bimanual technique using microforceps. The left anterior choroidal and PCOM aneurysms were completely exposed (**Figure 2B**). Externalized coils were observed over the deformed surface of the previously embolized PCOM aneurysm, generating mass effect over the third cranial nerve. In the first surgical stage, the PCOM aneurysm was clipped with a 10.5-mm straight Sugita T2 clip, and the externalized coils were removed, allowing decompression of the third cranial nerve. Subsequently, the anterior choroidal aneurysm was occluded with a curved Sugita T2 miniclip (**Figure 2C**).

Reinforcement of the PCOM aneurysm clip with a 7.0-mm curved Sugita T2 booster clip in a piggyback fashion was used to maintain closure, strength, and prevention of the initial clip from slipping (**Figure 2D** and **E**). Low-intensity micro-Doppler verified adjacent blood vessel patency posterior to clippage. The patient experienced a favorable postoperative period without complications. Postoperative angiography revealed patency and correct placement of the 3 clips used (**Figure 2F**).

DISCUSSION

In 1984, Sundt et al.⁶ introduced the concept of piggyback clipping and use of a booster clip for reinforcement of primary clips for the resolution of giant and thick-based aneurysms. They described its use in situations in which the closing pressure of a simple clip is not sufficient for complete neck occlusion and for the prevention of clip migration. Examples include giant aneurysms, which commonly have thick and wide bases; thickened aneurysmal walls from calcified or cholesterol plaques; and broad-based high-flow or high-pressure aneurysms, such as proximal carotid aneurysms located near the entrance of the artery into the cranial cavity. Thickened aneurysm bases predispose clip displacement onto the thinner walled parent artery, which can result in occlusion and subsequent ischemia.^{2,5} When calcium or cholesterol plaques are present, these alter proper clip placement by increasing the closing pressure required for complete occlusion and by displacement toward the parent vessel or toward the aneurysm fundus, generating suboptimal obliteration.² In addition, use of this technique can be advantageous over classical stacking techniques when facing pathologies with limited surgical exposure or narrow corridors. Reduction of the number of clips needed for occlusion can prevent visual obstruction owing to overcrowding of the operative field with multiple clips.

The closing force of clip blades has been found to be inconsistent along the blades, with the force strongest near the spring and weakest at the blade tips.⁷ To reinforce and maintain the closing pressure of the initial clip, the additional booster clip must be



Video available at
www.sciencedirect.com

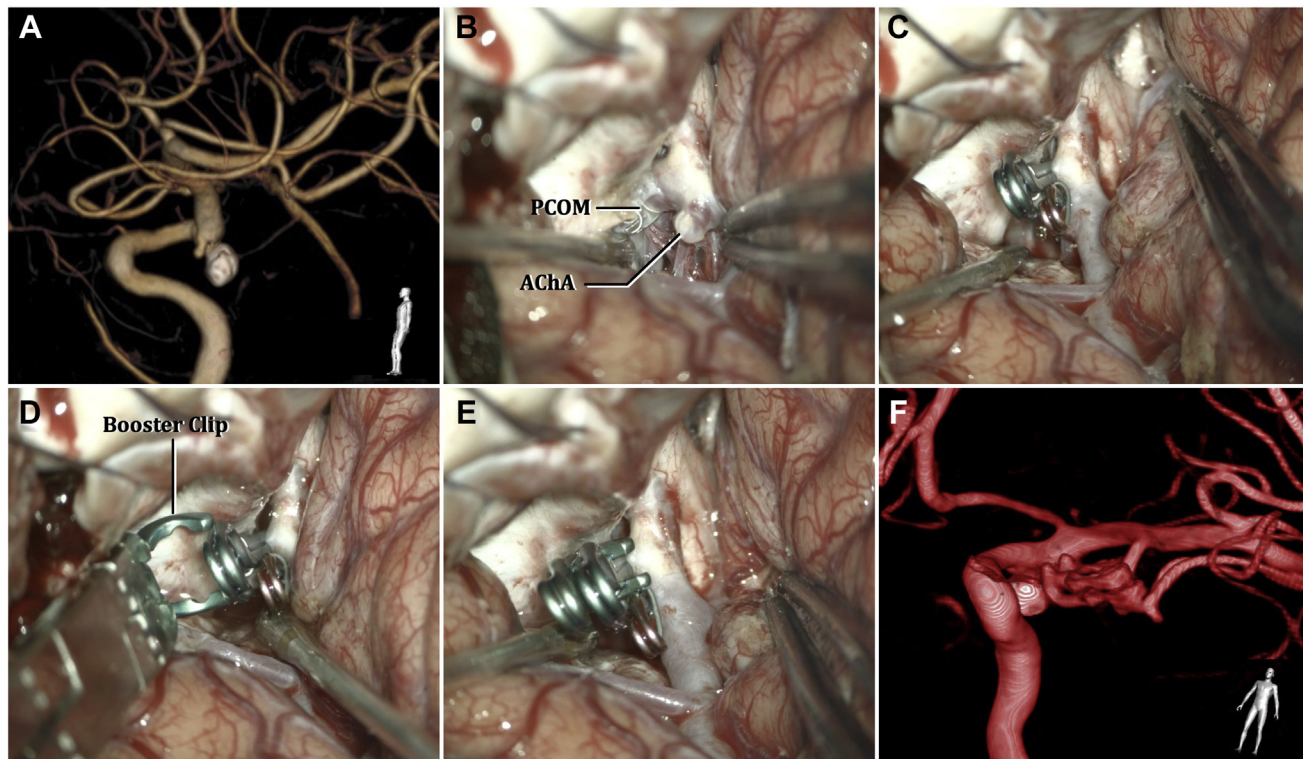


Figure 2. (A) Three-dimensional reconstruction of follow-up preoperative cerebral computed tomography angiography (lateral view). (B) Intraoperative view and exposure of the previously embolized left posterior communicating artery aneurysm and ipsilateral anterior choroidal aneurysm. (C) Initial clipping of both aneurysms. (D and E) Application of additional booster clip to the posterior communicating artery aneurysm. (F) Postoperative cerebral angiography displaying correct stacking technique and placement of aneurysm clips. PCOM, posterior communicating artery; AChA, anterior choroidal artery.

placed as close to the spring as possible and must securely grip the proximal part of the clip blades. The closing force is also inversely proportional to its length; hence when facing giant aneurysms requiring longer clips, incomplete neck occlusion or clip slippage is at risk. In this sense, booster clips are designed to provide a higher closing pressure than standard permanent clips, boosting or supplementing jaw compression. For this reason, they should never be applied directly over an aneurysm or blood vessel. As with standard clips, booster clips can have straight, angled, or curved blade patterns.

In our case, the decision to use the booster clip and piggyback technique was based on 2 reasons. The atypical morphology of the PCOM aneurysm (deformed from previous embolization) did not allow complete neck occlusion of the thickened aneurysmal neck with the initial clip, and therefore a multiple stacking technique was required. Considering that the additional clip over the anterior choroidal aneurysm within the operative field could possibly limit the clipping angles of additional clips over the PCOM aneurysm, the authors determined that reinforcement with a booster clip applied at the same angle was the best course of action. This was intended to avoid overcrowding the surgical field with more clips than necessary and the need of expansion of the surgical corridor for the application of clips at unusual angles. Essentially, the less is more paradigm was adopted. The initial clip used for this aneurysm demonstrated a closing force of 1.47

N, as do most standard permanent clips of this size, with a variability of $\pm 7.5\%$. To increase the closing force over the neck and ensure its closure, a 7.0-mm booster clip with a closing force of 2.75 N was applied, conferring an additional 87% (1.28 N) increase in closing force to the initial clip.

We would like to emphasize the limited content regarding this technique within the literature. Despite certain mentions as an alternative for particular cases, descriptions and specific details of the clip and technique in question are lacking. Furthermore, the term booster clipping has often been misused to refer to the placement of a clip next to or adjacent to the original clip, which is essentially considered tandem or parallel clipping. Although multiple smaller clips (either in tandem or parallel) are used more frequently than this technique, we believe that it is a helpful resource to be considered in certain situations for the vascular neurosurgeon. A potential complication of this technique is the formation of a "galvanic battery" owing to the placement of one clip directly over the other. In theory, creation of a galvanic battery carries the risk of corrosion and adjacent tissue toxicity. This problem was addressed and studied by Anderson et al.,⁸ who concluded that this can be prevented by use of similar metals for both clips. In modern times, it is rare to use dissimilar material clips during the same operative procedure, and therefore this complication is unlikely.

CONCLUSIONS

The piggyback stacking, or booster clip, technique is a useful alternative for the neurosurgeon's armamentarium. Booster clips provide an elevated mechanical closing force and are used for additional reinforcement of permanent clips when complete neck occlusion or prevention of clip migration cannot be guaranteed. Use of this technique should be considered for certain aneurysmal pathologies with risk of aneurysm clip slippage, such as in our case, which demonstrated an atypical morphology owing to previous embolization.

CRediT AUTHORSHIP CONTRIBUTION STATEMENT

Derek O. Pipolo: Conceptualization, Writing – original draft, Writing – review & editing, Project administration, Visualization. **Mickaela Echavarría Demichelis:** Resources, Visualization. **Cynthia Purves:** Resources, Project administration. **Alvaro Campero:** Conceptualization, Methodology, Supervision. **Juan F. Villalonga:** Writing – review & editing, Supervision. **Sabino Luzzi:** Writing – review & editing, Supervision. **Matias Bal-doncini:** Conceptualization, Methodology, Validation, Writing – review & editing, Supervision, Visualization.

REFERENCES

1. Lee KS, Zhang JJY, Nguyen V, et al. The evolution of intracranial aneurysm treatment techniques and future directions. *Neurosurg Rev.* 2022;45:1-25.
2. Horiuchi T, Hongo K. General principles of aneurysm surgery. In: Sekhar L, Fessler R, eds. *Atlas of Neurosurgical Techniques*. 2nd ed. New York, NY: Thieme Medical Publishers; 2016: 113-121.
3. Zhao J, Lin H, Summers R, Yang M, Cousins BG, Tsui J. Current treatment strategies for intracranial aneurysms: an overview. *Angiology.* 2018;69:17-30.
4. Lawton MT. Permanent clipping. In: *Seven Aneurysms: Tenets and Techniques for Clipping*. New York, NY: Thieme Medical Publishers; 2010: 16-20.
5. Misra B, Purandare H. Microsurgery of giant intracranial aneurysms. In: Sekhar L, Fessler R, eds. *Atlas of Neurosurgical Techniques*. 2nd ed. New York, NY: Thieme Medical Publishers; 2016: 301-321.
6. Sundt TM, Piepgras DG, Marsh WR. Booster clips for giant and thick-based aneurysms. *J Neurosurg.* 1984;60:751-762.
7. Horiuchi T, Rahmah NN, Yanagawa T, Hongo K. Revisit of aneurysm clip closing forces: comparison of titanium versus cobalt alloy clip. *Neurosurg Rev.* 2013;36:133-138.
8. Anderson RE, Bowron AM, Sundt TM. Biocompatibility analysis of the Sundt-Kees booster clip and the Drake aneurysm clip. Technical note. *J Neurosurg.* 1985;63:980-984.

Conflict of interest statement: The authors declare that the article content was composed in the absence of any commercial or financial relationships that could be construed as a potential conflict of interest.

Received 21 March 2022; accepted 23 May 2022

Citation: *World Neurosurg.* (2022) 164:306-309.
<https://doi.org/10.1016/j.wneu.2022.05.106>

Journal homepage: www.journals.elsevier.com/world-neurosurgery

Available online: www.sciencedirect.com

1878-8750/\$ - see front matter © 2022 Elsevier Inc. All rights reserved.